



Morphological identification of endoparasites in *Catla catla*

Pratima Chaudhary*, Kamal Jaiswal, Swati Singh

Department of Zoology, Babasaheb Bhimrao Ambedkar University, Raibareli, Lucknow, Uttar Pradesh, India

Abstract

The study was conducted to evaluate the endoparasitic infection in fresh water Indian major carp i.e., *Catla catla* (*thaila*). Fishes were randomly collected from the various water sources like Aurangabad fish pond, near Ramabai Ambedkar Park, Lucknow, Gomti river front, Lucknow, Bani sai river, near Ramada hotel, Lucknow, and Nadarganj pond, near airport, Lucknow, and Fish Pond in Scooter India, near Police Chauki, Lucknow, Uttar Pradesh etc. During the period from January 2022 to June 2022. Total 41 *catla catla* fishes were visually inspected and were dissected in the laboratory out of which 21 Fishes were found infested with the parasites. Fishes were showing the parasitic infestation of Acanthocephalans in intestine of the fish. The prevalence and mean intensity of acanthocephalan infection in *Catla catla* fish found was 51.2 % and 2.0 respectively. Identification of parasites was done using light microscope and scanning electron microscope. The present study explains the morphological identification of Acanthocephalan found in host *Catla catla*.

Keywords: morphology, acanthocephalan, endoparasite, host fish *catla catla*, scanning electron microscope

Introduction

Fishes are an important source of protein and provide employment to about 14 million people in aquaculture. Indian fishes contribute about 6.3% of the global fish production and shares 1.07% of the GDP (Soibam Ngasotter *et al.*, 2020) [18]. Host fish *Catla catla* is commonly called as Bhakhur and it is one of the fastest growing Indian major carp with increasing demand (Brraich *et al.*, 2022) [5]. *Catla catla* is one of the major carp produced from the aquaculture in India (Pal Gaurav Kumar, T. Nidheesh, P.V. Suresh *et al.*, 2015) [20]. After China, India is the largest producer of freshwater fishes in the world (Pal Gaurav Kumar *et al.*, 2015). Fish population and food value is directly affected by the fish parasites. Keeping the eye on the increasing population rate, fish is one of the recognized and better appreciated foods in such increasing malnutrition scenario. Throughout the world efforts are made to exploit the healthy fishes but a large number of fishes may become non palatable due to parasitic infestation in fishes (Sh. M.A. Abdullah *et al.*, 2004) [1]. The parasites are those organisms which reside in other organism body called host. Parasitism is a kind of animal association and ecological relationship between two heterospecific organisms. Parasites attack various organs of the fish like gills, intestines, dermis or epidermis, kidney, gall bladder etc. Fishes are infected with the minimum two kinds of parasites that are endoparasites and ectoparasites (Dr. G. N. Bhagya Rekha., 2015) [24]. Each and every parasite which belongs to the freshwater community has its own special way of transmission (Sh. M.A. Abdullah *et al.*, 2004) [1]. Almost all the fishes serve as intermediate or final hosts for the parasites (Dr. G. N. Bhagya Rekha., 2015) [24]. Also, freshwater fishes are known for acting as intermediate host. They carry various larval stages of the cestodes, nematodes which are pathogenic for the fish consuming animals (Sh. M.A. Abdullah *et al.*, 2004) [1]. Acanthocephalans are recognized

by their evaginable proboscis which is surrounded by the rows of hooks (FAO, 1996; Iyaji, F. O. Eyo, J. E). Differentiation of the species is done on the basis of number of rows of hooks and their arrangement on proboscis region (Kabata, 1985). Adult worms are usually found in gut and it lacks alimentary canal (FAO, 1996). Pathogenic effect is due to the attachment in the alimentary canal and encapsulation of the larval stages in the tissue, damages is directly proportional to the depth of penetration (FAO, 1996; Oniye *et al.*, 2004) [19]. Acanthocephalan impacts the absorptive efficiency of the fish intestine (shahana perveen *et al.*, 2019). Using their hook bearing attachment organ proboscis damages the host tissue in alimentary canal. Many times, proboscis movement causes inflammatory reactions, induces bleeding, lesions and narcosis, which could reduce the host nutrients absorption ability. Acanthocephalans can significantly increase mortality rate (Katharina Mauer *et al.*, 2020) [16].

Host specificity of acanthocephalan varies because it infects large species of fish's family (Khalil, 1971; Troncy and Vassillides, 1973; Troncy, 1974; 1977; Batra, 1984; Dovellou, 1992a, b; and Oniye *et al.* 2004) [3, 9, 19]. Apart from all the above-mentioned parasites in fish's protozoan, bacterial, viral and fungal infections is frequently noticed. In the present study *Catla catla* were collected and examined for endoparasites and their morphological identification was done via light and scanning electron micrography.

Materials and methods

Sampling-*Catla catla* fishes were collected from Aaurangabad pond, gomti river front, Jiamau (Gomit river), Bani Sai River front, Ndarganj Pond and scooter India pond, Lucknow, Uttar Pradesh. In each sampling minimum 2 fishes were collected from various sources as mentioned above. In livable condition fishes were brought to the laboratory using water filled buckets. Visual inspection of

the fishes was done and fishes were identified as male or female by looking at the urinogenital system. Length and weight of the fishes were done by using rural scale and weighting machine respectively. Gills, fins, skin and scales of fishes were inspected thoroughly for ectoparasite.

1. Dissection of collected samples

The fishes were immobilized by cervical dislocation for easy handling prior to dissection. The fishes were dissected through the abdomen by making a longitudinal slit on the ventral surface from the anus to a point level with the pectoral fins using a surgical blade or sharp pair of scissors. The alimentary canal was isolated stretched out and grouped into intestine and gall bladder. Sections were placed in separate petri dishes containing 0.6 % saline (Kawe *et al.*2016). Fat was removed from the intestine and then the intestine was dissected using point, sharp pair of scissors. Intestine was finally spread using the pointed forceps and brush. Thoroughly, observed the spread intestine with naked eyes. Suspected specimens were collected in a separate Petri dish containing water. After collection of the suspects, they were observed under the microscope to confirm whether it is parasite or not. After confirmation parasites were separated as per the category it belongs. Confirmed parasites were preserved by making temporary or permanent slides.

2. Parasite processing for light microscope-After

separation of acanthocephalans, they were washed with the distilled water or luke water then these parasites were transferred to the 70% hot alcohol+glycerol (95:5) for at least 24 hours after that parasites were transferred to the Lacto phenol in order to make the tissue and organs transparent. Then, viewed under microscope after that, mounted with the DPX for permanent slide.

3. Sample preapartion protocol for SEM (scanning electron microscope)

Specimen with size of 2-4mm was collected. Sample was fixed in 2.5% Glutaraldehyde for 2-6 hours at 4 degrees Celsius. Sample was washed in 0.1 M Phosphate Buffer, for 3 changes of 15 min at 4 degrees Celsius, and then it was washed in 0.1 M Phosphate Buffer for 3 changes each of 15 minutes at 4 degrees Celsius to remove the unreacted fixative. After that, specimen was dehydrated using increasing concentration of Acetone to remove water 30%, 50 %,70%,90% acetone and in 100% (Dry Acetone) for 30 minutes and all Steps were carried out at 4 degree Celsius. Specimen was dried by Air Drying. After that, Specimens were mounted on to the Aluminum Stubs with Carbon tapes. Finally, Sample was dried by CPD coated using sputter coater to make the sample conductive and observed under Scanning Electron Microscope at BBAU, USIC.

Results

Total 41 *Catla catla* fishes were dissected in the laboratory out of which 21 Fishes were found infested with the 43 parasites. Fishes were showing the parasitic infestation of Acanthocephalans. Random sampling and fish parasite collection was done and the data were tabulated in Table 1.

Morphological characters observed under microscope

Collected Acanthocephalans collected were creamy whitish in colour and was easily recognized and identified by their envaginable proboscis along with this proboscis was crowned with different rows of hooks, numbers of rows of hooks was responsible for the differentiation of the species. There was no alimentary canal was seen during observation of the parasite. Body was elongated and clubbed shaped. In and out movement of the proboscis was seen along with this it was noticed that the acanthocephalans were varying in size representing their male and female nature. Behind proboscis short unarmed neck was visible. Entire body was covered with the spines. The trunk region was observed with the transverse rows of spines up to the mid length of the body or little beyond number of hooks was decreasing from anterior to posterior region.

Figure 1 (A, B, C) *Catla catla* parasites were observed under the light microscope figure A shows unarmed short neck, proboscis along with the various rows of hooks were observed under 10X, figure B shows the posterior region of the Acanthocephalan and figure C shows whole mount of Acanthocephalan was observed under 4X.

Morphological characters observed under Scanning Electron Microscope

Hooks were triangular in shape and broad end was embedded into the body wall of the parasite were as the pointed end was directed towards the posterior side. Hooks present at the anterior region were different from the hooks present in middle of the body. Anterior hooks were densely present whereas middle hooks are not densely present or we can say that anterior region greater number of hooks rings when compared with middle portion. Posterior end was broader as compared with the anterior end. Both the ovaries were elongated and arranged in tandem in the ligament sac. There were two different testes located post equatorially.

Figure 2 collected parasite is observed morphologically identified under scanning electron microscope figure (2A) shows the anterior portion bearings number of rows of hooks which are of different length, (2B) round shaped structure represents the posterior region of the acanthocephalan, (2C) depicting the pointed triangular shaped hooks which are pointing towards the posterior region and the wider end was embedded into the surface. (2D) showing the whole mount of the parasite.

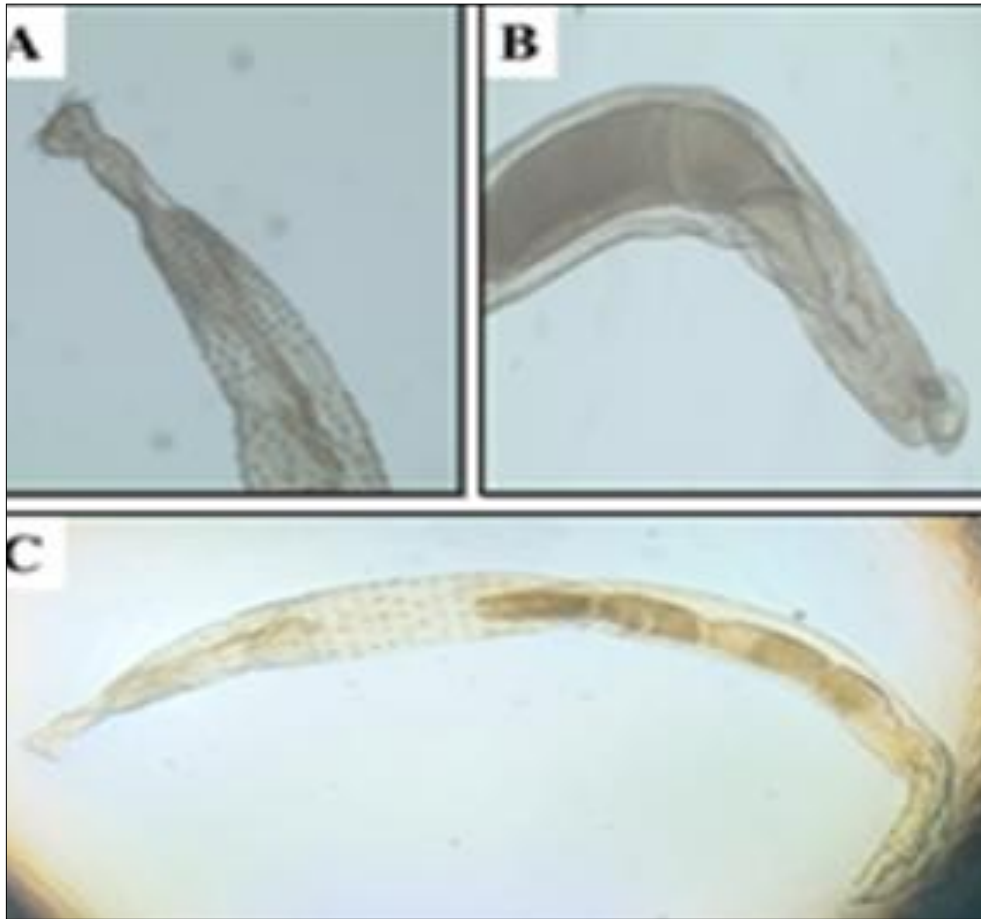


Fig 1: A) Anterior region of Acanthocephalan depicting proboscis, unarmed short neck and various number of rows of hooks which are pointing towards the posterior region (microscopic view under 10X); B) Posterior region of Acanthocephalan. (Light microscopes under 10X; C) whole mount of male Acanthocephalan recovered from the *Catla catla* fish. (Microscopic views under 4X)

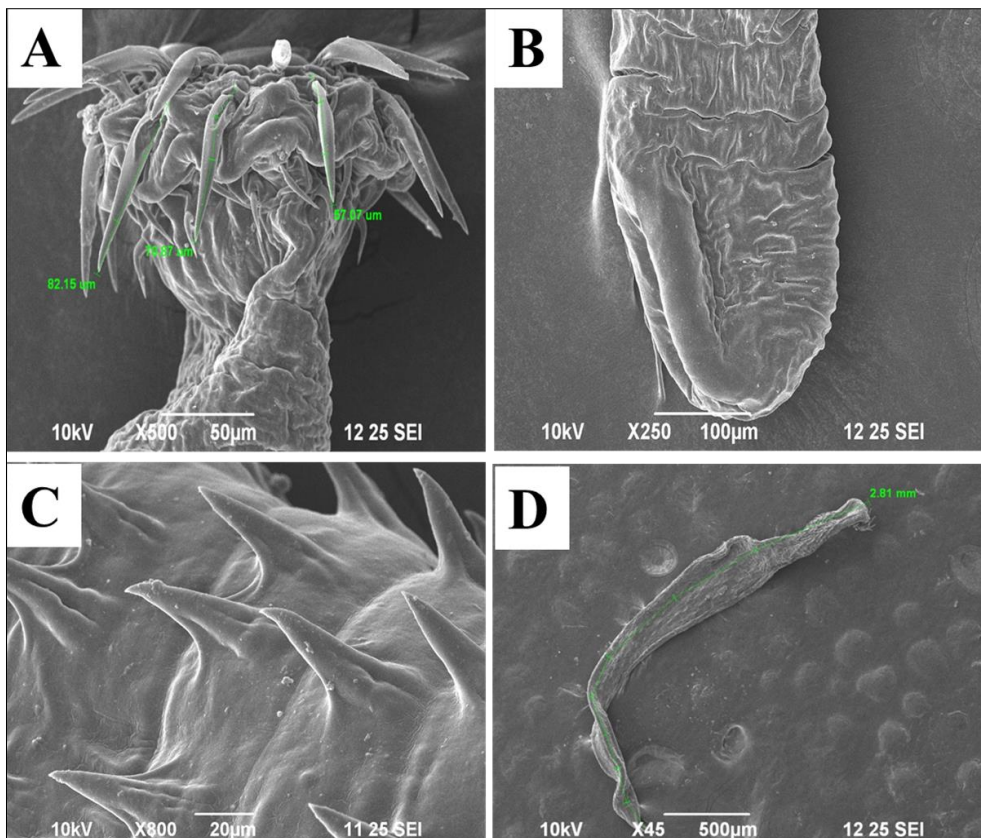


Fig 2: (A) Anterior portion of the Acanthocephala, (B) Posterior portion of the acanthocephalan, (C) hooks pointing towards posterior (D) whole mount of the Acanthocephala (captured from scanning electron microscope)

Table 1: Random sampling and fish parasite collection.

s.no	Date of examination	Site of collection	no. of infected <i>Catla</i> fish examined	Number of parasites collected
1	25/02/22	Aurangabad fish pond, near Ramabai Ambedkar Park, Lucknow, Uttar Pradesh	02	05
2	02/03/22	Gomti river front, Lucknow, Uttar Pradesh	03	04
3	05/03/22	Bani sai river, near Ramada hotel, Lucknow, Uttar Pradesh	02	04
4	15/03/22	Aurangabad fish pond, near Ramabai Ambedkar Park, Lucknow, Uttar Pradesh	03	05
5	22/03/22	Fish pond in Scooter India, near near Police Chauki, Lucknow, Uttar Pradesh	03	05
6	25/03/22	Gomti river front, Lucknow, Uttar Pradesh	02	04
7	27/03/22	Bani sai river, near Ramada hotel, Lucknow, Uttar Pradesh	02	04
8	30/04/22	Aurangabad fish pond, near Ramabai Ambedkar Park, Lucknow, Uttar Pradesh	02	04
9	02/04/22	Gomti river front, Lucknow, Uttar Pradesh	03	03
10	05/04/22	Nadarganj pond, near airport, Lucknow, Uttar Pradesh	02	05

Discussion

Present study was conducted on *Catla catla* fish to determine the parasitic infestation. Total 41 fishes were examined in the laboratory out of which 21 fishes were found to be infected with acanthocephalan. Total numbers of parasites collected were 43, which were collected from the intestines of the fish. Collected parasites were whitish in colour. In and out movement of the proboscis was noticed. After proboscis there was short unarmed neck was present. Entire body was elongated and clubbed shaped, surrounded by the spines. Anterior portion was having rows of hooks; numbers of rows of hooks are responsible for the differentiation of the species. The trunk region was observed with the transverse rows of spines up to the mid length of the body or little beyond number of hooks was decreasing from anterior to posterior region. Hooks were triangular in shape and broad end was embedded into the body wall of the parasite and the pointed end was directed towards the posterior side. Hooks present at the anterior region were different from the hooks present in middle of the body. Anterior hooks were densely present whereas middle hooks are not densely present or we can say that anterior region greater number of hooks rings when compared with middle portion. Posterior end was broader as compared with the anterior end. Both the ovaries were elongated and arranged in tandem in the ligament sac. There were two different testes located post equatorially. Present SEM study revealed proboscis with spines having various rows of hooks which were alternatively arranged and were directed towards the posterior region. The prevalence and mean intensity of acanthocephalan infection in *Catla catla* fish found was 51.2 % and 2.0 respectively. Similar findings were recorded by the other scientists; they characterized acanthocephalans by the possessions of head called a proboscis bearing hooks and spines that enable them to attach to the intestinal wall of their definitive host. Nutrients are absorbed by the body wall due to lack of digestive system (DJ Richardson, 2008) [25]. The invaded acanthocephalans were attached to the gut wall (Omar M. Amin *et al.*, 2011). Circle of hooks were seen on the body of the acanthocephalan parasite, number of hooks were declining in size and number from anterior to posterior region, hooks were rooted and directed towards posterior end, neck was short and unarmed. Trunk region was dividing into two regions, anteriorly with 15-16 circles of hooks which were presented in comb like structure (K Rana *et al.*, 2019). Hooks were directed towards the posterior side. Hooks were decreasing in size from anterior to posterior side of the body. Body was whitish and

cylindrical in colour (Pinky Kaur *et al.*, 2021). Entire body was cylindrical and elongated with spiny proboscis. Several rows of hooks were evenly distributed. after proboscis there was short neck which was free from the spines (E. K. A. BAZH *et al.*, 2009) Acanthocephalans were termed as the obligate parasites of the vertebrates, mostly of the fishes. (Susanne Reier *et al.*, 2020). In the alimentary canal, worms usually grow to adults of several millimeters to a few centimeters in length, followed by heterosexual reproduction. Upon insemination, the female produces large quantities of eggs containing a larval stage (acanthor). The eggs are released into the environment with the host's excrement and subsequently can be orally taken up by an intermediate host from Crustacea, Hexapoda or Myriapoda. Inside the intermediate host, the acanthor grows to a stage, which can infect the definitive host, following oral uptake of an intermediate host (Katharina Mauer *et al.*, 2020) [16]. All acanthocephalans exhibit an indirect life cycle utilising an arthropod intermediate host (DJ Richardson, 2008) [25]. Generally, in unfavorable conditions acanthocephalans penetrates the intestinal wall of the host organism, which can elicit inflammation. These migrating worms enter in mesenteries and various organs such as liver, with serious consequences for host health. Using their hook bearing attachment organ proboscis damages the host tissue in alimentary canal. Many times, proboscis movement causes inflammatory reactions, induces bleeding, lesions and narcosis, which could reduce the host nutrients absorption ability. Acanthocephalans can significantly increase mortality rate (Katharina Mauer *et al.*, 2020) [16]. they can also tissue injury, cause malnutrition, and intestinal obstruction in hosts, Infection of these parasites may result in poor growth, postpone sexual maturity and mortality of fishes, cause human and animal diseases (Sanjeev Kumar Verma *et al.*, 2018) [31]. Apart from the present there are other SEM studies which supports the present study number of hooks were decreasing from anterior to posterior region (SH Sheema *et al.*, 2017) [26]. Other SEM study revealed that there were 11-14 longitudinal rows along with 9-12 recurrent, backward- facing and organised hooks (Li-Wu Chenget at., 2022). As per the other researchers the prevalence found was 38-6%. (I. R. Smales *et al.*, 2018) [27]. Overall prevalence and mean intensity of piscine acanthocephalians were 16.30% (Tolulope Ebenezer Atalabi *et al.*, 2018) [2]. The total prevalence of infested fishes with acanthocephalans was 30%. (M El-lamie *ET AL.*, 2018) [10]. Prevalence and intensity depends upon many factors like temperature, type of host and feeding habit etc. (Sanjeev Kumar Verma *et al.*, 2018) [31]

Conclusions

Parasitology is a branch of science which deals with the study of parasites and discipline dealing with the biology of parasite (including its morphology, embryology, physiology, biochemistry and nutrition etc.), ecology of parasitism with emphasis on parasite-host and parasite environment interactions. Parasites are host specific as well as environment specific. A parasite acquires their nutrition from the host organisms and causes damage to their body sometimes death of the host organism. Usually parasites are smaller in size as compared to host organism. Major carp Cat la catla fish is host organism which harbors parasites like Acanthocephalans, cestodes, trematodes, nematodes, protozoa, bacteria, virus and fungus. Catla catla is one of most important aquaculture freshwater fish species in south Asia. It is generally grown in polyculture pond with Labeo rohita and Cirrhinus mrigala. It is mainly used for food purpose, and it is one of the fastest growing fish its demand is increasing day by day in the market. In present study host organism harbors Acanthocephala which was collected the gastrointestinal tract of the fish. There might be lots of reasons for infestation of these parasites like poor management, poor water quality, lack of quarantine measures, lack of nutrition etc all these factors needs to be improved because these are negatively impacting impacting for the health of the fishes. Hence, causing loss in economy of the country.

Acknowledgements

Authors gratefully acknowledged the support provided by Department of Zoology, BHU for the finalizing the data of the manuscript.

Conflict of Interest

No conflict of interest declared.

References

1. Abdullah SM, Rasheed ARAM. Parasitic fauna of some freshwater fishes from Dokan lake, north of Iraq. II: Endoparasites. *Ibn Al-Haitham J. Pure Appl. Sci*,2004:17(5):1-12.
2. Atalabi TE, Awharitoma AO, Akinluyi FO. Prevalence, intensity, and exposed variables of infection with Acanthocephala parasites of the gastrointestinal tract of *Coptodon zillii* (Gervais, 1848) [Perciformes: Cichlidae] in Zobe Dam, Dutsin-Ma Local Government Area, Katsina State, Nigeria. *The Journal of Basic and Applied Zoology*,2018:79(1):1-7.
3. Batra V. Prevalence of helminth parasites in three species of cichlids from manmade lake in Zambia. *Zoological Journal of Linnaean Society*,1984:82:319-333.
4. Bazh EKA, Hamouda AH. Scanning morphology, prevalence and histopathology of some acanthocephalans infecting some River Nile fish. *Bulgarian Journal of Veterinary Medicine (online first)*, 2019, 2019-0087.
5. Braich OS, Kaur L. Comparative studies on age and growth patterns of cultivated and wild Catla catla (Hamilton). *Indian Journal of Experimental Biology (IJEB)*,2022:60(02):144-149.
6. Chai JY, Murrell KD, Lymbery AJ. Fish-borne parasitic zoonoses: status and issues. *International journal for parasitology*,2005:35(11-12):1233-1254.
7. Cheng LW, Rao S, Wang PC, Chen SC. First report of acanthocephalan parasite, *Longicollum pagrosomi* Yamaguti, 1935 in cultured red snapper (*Lutjanus erythropterus*) in Taiwan. *Journal of Fish Diseases*,2022:45(4):579-593.
8. Dash G, Sharma BB, Chakraborty D, Mukherjee D. Parasitic study of Indian major carp Catla catla (Hamilton, 1822) in selected districts of West Bengal, India. *International journal of advanced scientific and technical research*,2015:1(5):75-83.
9. Dovellou L. A survey of fish parasites in lake Kariba, Zimbabwe (1989-1992) Final Report. University of Zimbabwe, Lake Kariba Research Station Bulletin,1992a:1:71-92.
10. El-lamie M, Abdel-Mawla HI. Investigation of Acanthocephalan parasites in some marine fishes as a bio-indicator for heavy metals pollution. *Egyptian Journal for Aquaculture*,2018:8(1):13-30.
11. Food and Agriculture Organization of the United Nations (FAO). Parasites, infections and diseases of fishes in Africa - An Update. Committee for Inland Fisheries of Africa (CIFA), Technical Paper No. 31. FAO, Rome, 1996, 220.
12. Geetarani B, Shomorendra M, Vishweshwari A, Devashish K, Jha AN. Helminthic infection in relation to the host length and sex in some freshwater fishes, *Anabas testudineus* (Bloch) and *Channa gachua* (Ham.). *Biospectra*,2010:5(2):233-236.
13. Iyaji FO, Eyo JE. Parasites and their freshwater fish host. *BioResearch*,2008:6(1):328-338.
14. Kaur P, Shamal P, Chandran A, Sharma S, Sanil NK. Characterization of *Filisomargusum* n. sp. (Acanthocephala: Cavisomatidae Meyer, 1932) infecting the spotted scat, *Scatophagus argus* (Linnaeus, 1766) from the Indian coast. *Parasitology Research*,2021:120(7):2505-2521.
15. Koehleuther. in view of taxonomic misidentifications, intraspecific variability and possible cryptic species. *Parasitology*,1771:147(13):1499-1508.
16. Mauer K, Hellmann SL, Groth M, Fröbius AC, Zischler H, Hankeln T, Herlyn H. The genome, transcriptome, and proteome of the fish parasite *Pomphorhynchus laevis* (Acanthocephala). *PLoS One*,2020:15(6):e0232973.
17. Monir S, Bagum N, Rahman S, Ashaf-Ud-Doulah M, Bhadra A, Borty SC. Parasitic diseases and estimation of loss due to infestation of parasites in Indian major carp culture ponds in Bangladesh. *Int J Fish Aquat Stud*,2015:2:118-122.
18. Ngasotter S, Panda SP, Mohanty U, Akter S, Mukherjee S, Waikhom D, Devi LS. Current scenario of fisheries and aquaculture in india with special reference to Odisha: a review on its status, issues and prospects for sustainable development. *International Journal of Bio-Resource & Stress Management*,2020:11(4):370-380.
19. Oniye SJ, Adebote DA, Ayanda AI. Helminth parasites of *Clarias gariepinus* (Teugels) in Zaria, Nigeria. *Journal of Aquatic Sciences*,2004:19(2):17-75.
20. Pal GK, Nidheesh T, Suresh PV. Comparative study on characteristics and *in vitro* fibril formation ability of acid and pepsin soluble collagen from the skin of catla (*Catla catla*) and rohu (*Labeo rohita*). *Food Research International*,2015:76:804-812.

21. Perveen s, sahay dD. Analysis of incidence of acanthocephala in freshwater fishes channa punctatus and channa striatus of chapra,(bihar).
22. Rana K, Kaur H. Morphological and molecular description of *Pallisentis roparensis* n. sp. (Acanthocephala: Quadrigyridae) infecting the freshwater cat fish *Wallago attu* from Ropar Wetland, Punjab, India. *International Journal for Parasitology: Parasites and Wildlife*,2021;16:244-254.
23. Reier S, Sattmann H, Schwaha T, Fuehrer HP, Haring E. Unravelling the hidden biodiversity—the establishment of DNA barcodes of fish-parasitizing Acanthocephala, 2020.
24. Rekha GB. Morphology and Morphometry of Acanthocephalan, *Acanthogyrus* found in Fish Host *Catla catla* of Hyderabad and Rangareddy Dist, (2015).
25. Richardson DJ. Acanthocephala. *eLS*, 2008.
26. Sheema SH, John MV, George PV. SEM studies on acanthocephalan parasite, *Echinorhynchus veli* infecting the fish *Synaptura orientalis* (Bl & Sch, 1801). *Journal of Parasitic Diseases*,2017;41(1):71-75.
27. Smales LR, Adlard RD, Elliot A, Kelly E, Lymbery AJ, Miller TL, Shamsi S. A review of the Acanthocephala parasitising freshwater fishes in Australia. *Parasitology*,2018;145(3):249-259.
28. Troncy PM. Recherches sur les cestodes nématodes et acanthocéphales, parasites des poisson d'eau douce du bassin Tchadien. PhD Thesis Université des Science et Technique du Languedoc, 1977.
29. Troncy PM. Acanthocéphales parasites de poisson d'Afrique II. *Bull Inst. Fond. Afr. Noire (A. Sci. Nat)*,1974;36:902-910.
30. Troncy PM, Vassilides G. Acanthocéphales parasites de poisson d'Afrique I. *Bull. Inst. Fond Afr. Noire (A. Sci. Nat.)*,1973;35:522-539.
31. Verma SK, Yadav S, Saxena AM. An ecological analysis of acanthocephalan parasites of *Channa punctatus* of river Gomti, Lucknow, Uttar Pradesh, India. *International Journal of Zoology Studies*,2018;3(2):01-04.